

**Report Requested By**  
REDACTED FOR PRIVACY



**Report Provided By**  
Dr. Bob O'Brien DVM, DACVR  
service@peregrinerad.com  
Mobile: 513.655.3157  
901 Calle Amanecer; Suite 150  
San Clemente, CA 92673  
<http://www.Peregrinerad.com>

**PEREGRINE-2020-010033**

**Patient: Oliver**

Canine | Mix | 6 months | Male | 61.6 lbs | 192089

**Closed:** 2020-12-21 09:21  
**Date Opened:** 2020-12-21 06:59  
**Submitted:** 2020-12-20 16:48

## Admin Details

### Services

Diagnostic Imaging - CT (single site)

## Clinical Findings

### History & Clinical Signs

Acute swelling associated with unerupted #405, Fine needle aspirate was unremarkable. No overt evidence of infectious/inflammatory process. differential diagnosis Dentigerous cyst r/o infectious, cancerous process  
Rob Reigle DVM

### Current Medications

Gabapentin 300 mg q 8-12 hr.

Clavamox 375 mg q 12 hr.

Prednisone 20 mg q 24 hr.

**Drugs or Sedation Used** Hydromorphone/dexdomitor/propofol

**How are Images Submitted?** DICOM

**Date Of Most Recent Images** 2020-12-18

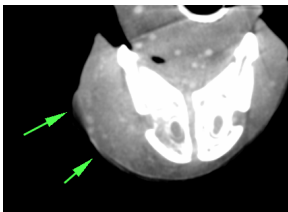
## CT Report

### Findings

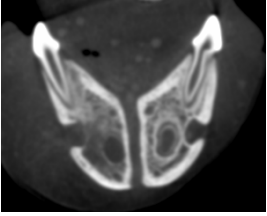
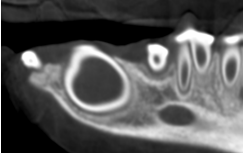
Survey and post-i.v. contrast CT of the skull

Nasal Cavity: No fluid or mass seen. No turbinate lysis or deviation or lysis of the septum

Oral cavity: Poorly marginated soft tissue swelling with fat stranding in the region of the 405



Dentition: periodontal lysis is seen surrounding the root of 405. No missing teeth seen. Poorly marginated lysis of the mandible in the root region of 404 and 404.



Orbital structures appear normal.

Frontal sinuses: Right side and left side air filled. No frontal bone lysis seen

Ventral nasal meatus: air filled

Nasopharynx: air filled

Nasal vault: No maxilla, nasal bone or hard palate lysis seen

Cribriform plate: no lysis seen

Brain: No evidence of aberrant meningeal contrast enhancement or deviation of the falx. Pituitary gland normal size (5.7 mm tall)

Tympanic Bullae: air filled and no bulla wall lysis or thickening seen. hyperostotic tympanic bone spicules (HTBS)

External ear canals: air filled and no wall thickening

Temporomandibular joints (TMJ's) appear normal

Mandibular LN's: symmetrical normal shape and size (7.6 mm wide)

Medial retropharyngeal LN's: symmetrical normal shape and size (10.3 mm wide)

Thyroid glands: symmetrical normal shape and size (3.6 mm wide)

#### **Conclusion**

Rostral right mandibular region selling and mandibular lysis: possible osteomyelitis; periapical infection, septic focus, lucent foreign body

#### **Recommendations**

Antibiotic therapy and recheck in 7-10 days

fungal titers as geographically relevant

Oral examination for lesions of teeth 404, 405

**Signed:**

A handwritten signature in black ink, appearing to read "Bob O'Brien".

Dr. Bob O'Brien DVM, DACVR